



## Summary Feedback

(Combined feedback broadcasted at multiple times this week)

### **PRE-RECORDED: Basildon FRCR 2B 'A to Zee' Course 2020**

## **Session 2/38**

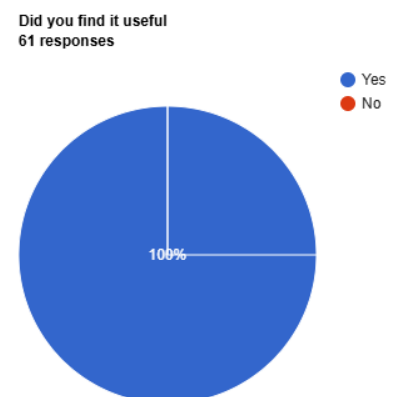
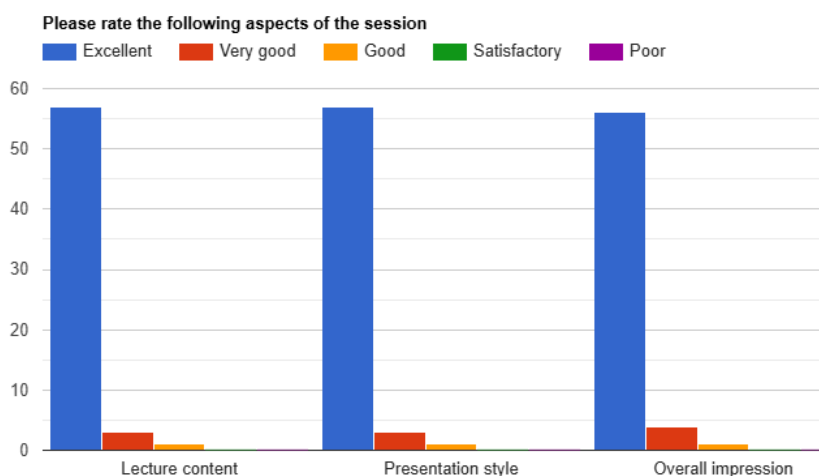
### **Chest X-Ray for FRCR Exam Part-2**

**(22<sup>nd</sup> & 23<sup>rd</sup> March 2025)**

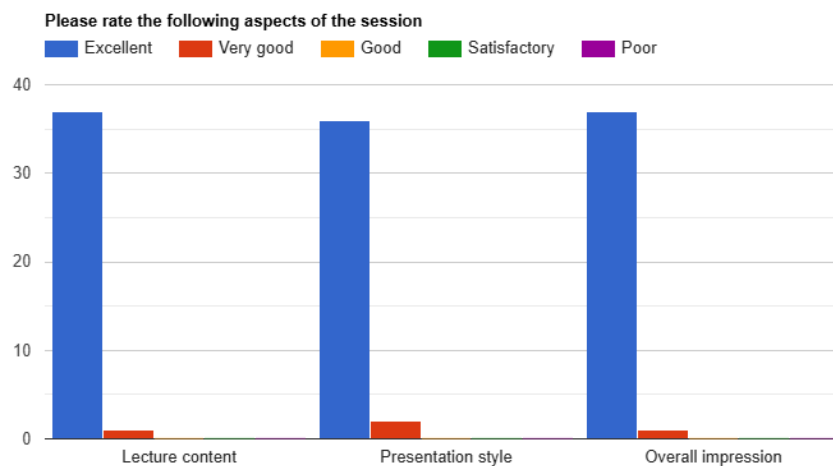
**Lecturer: Thaj Rehman**

#### **Summary Points:**

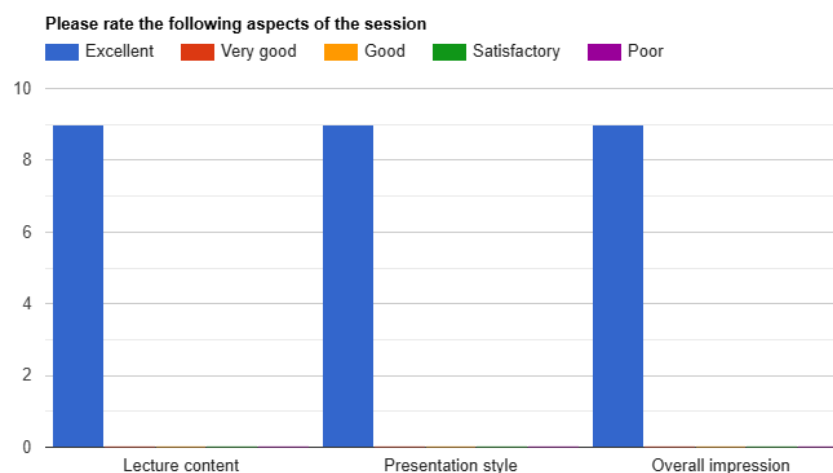
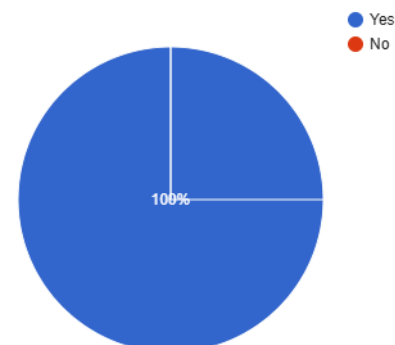
- Total Attendees: 375 from 31 Countries (Algeria, Bangladesh, Dominica, Egypt, Ghana, Hong Kong, India, Indonesia, Iraq, Jordan, Kenya, Kuwait, Libya, Malaysia, Netherlands, Nigeria, Norway, Oman, Pakistan, Qatar, Saudi Arabia, Singapore, South Africa, Sri Lanka, Sudan, Swaziland, Türkiye, UAE, UK, Yemen, Zimbabwe).
- Total duration: 2.5 hours (each session broadcasted thrice during the week)
- Total feedback received from 108 participants, from three different broadcasts



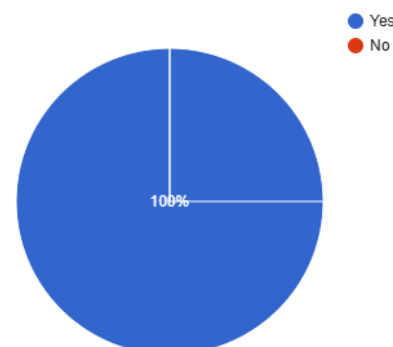
## Chest X-Ray For FRCR Exam Part-2



Did you find it useful  
38 responses



Did you find it useful  
9 responses

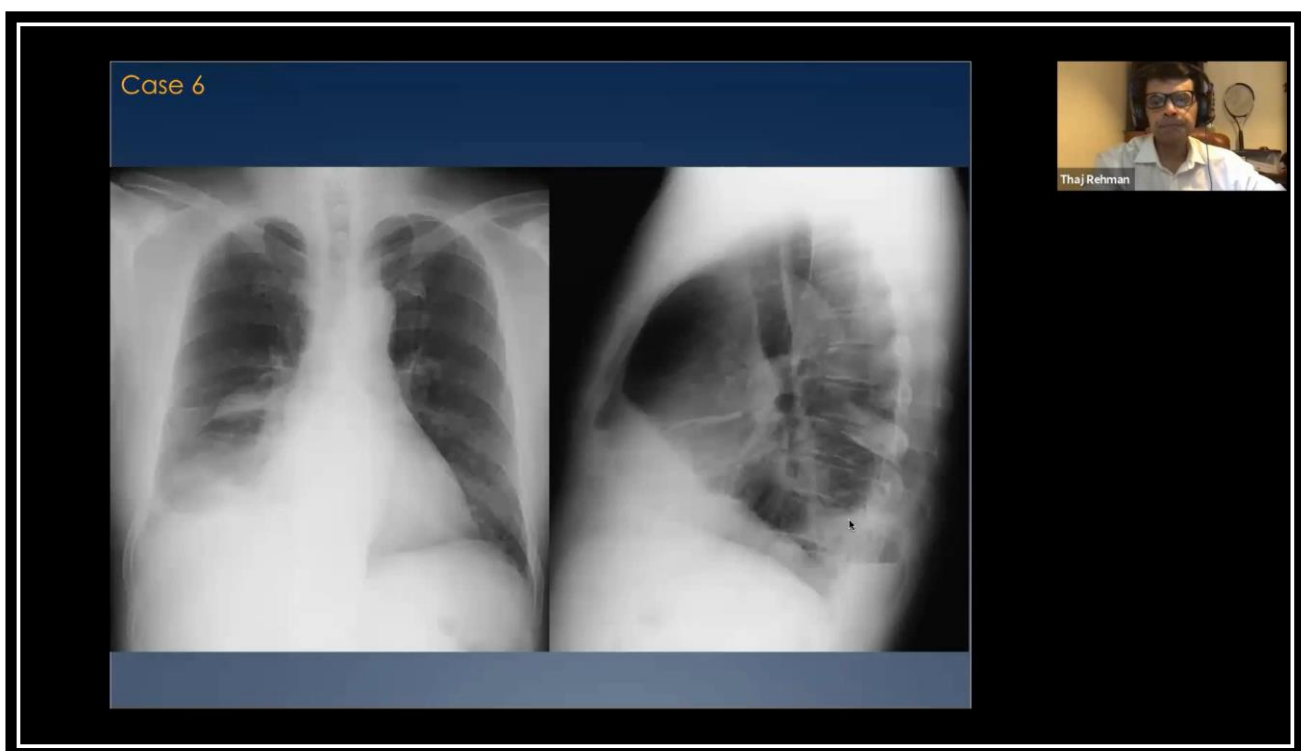
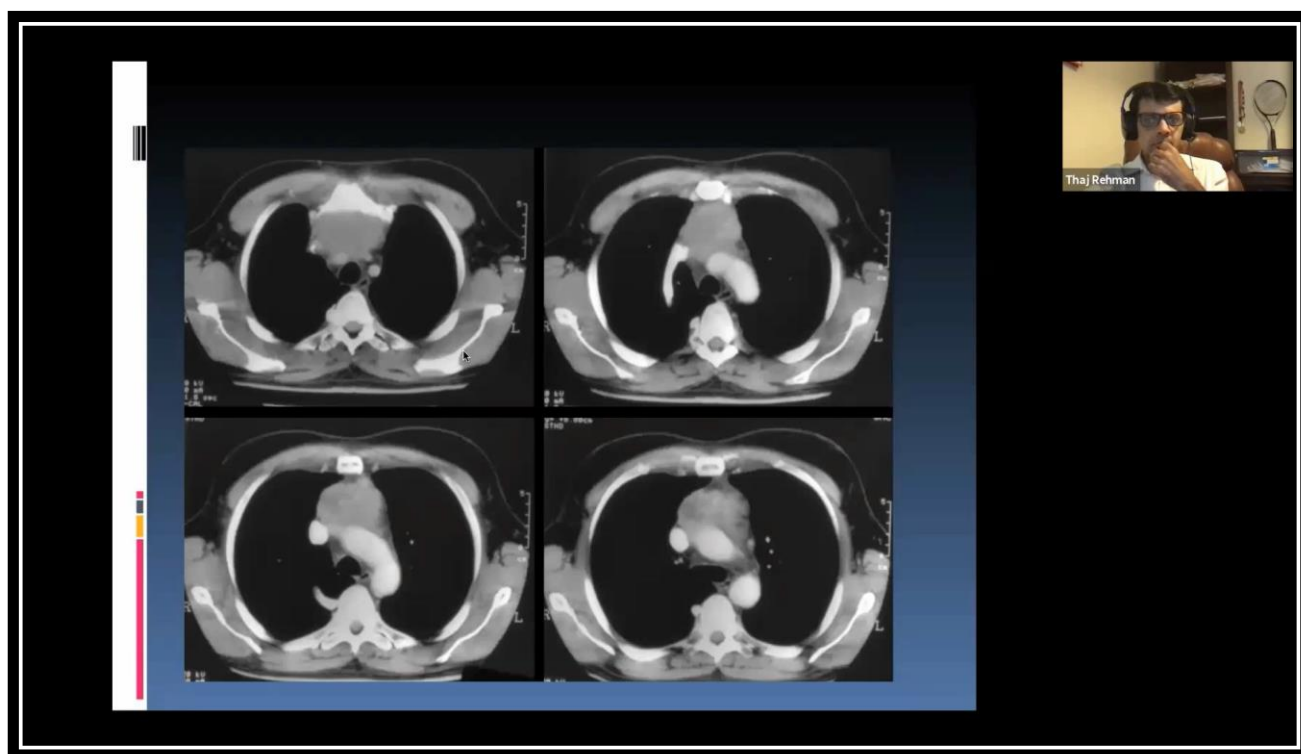


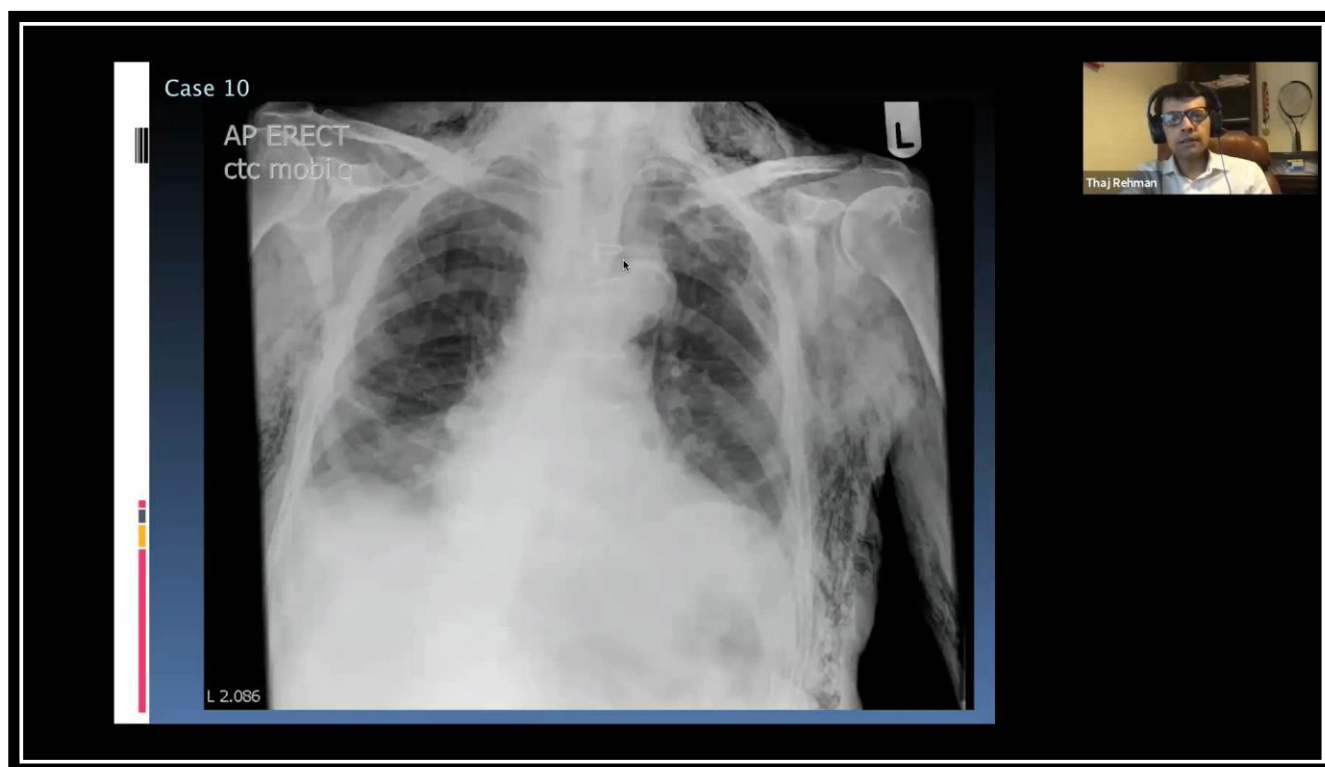
## Testimonials

- I really appreciate the wealth of cases as well as demonstration of different views and CT correlation. A lot of fine touch nuggets were shared today, overall great lecture (Zimbabwe).
- Very well taught in simple ways, diverse thoracic imaging cases with emphasis on both exam oriented as well as practical points of reporting (India).
- Numerous interesting chest radiographs and discussion shared (Malaysia).
- It was a great lecture (Ghana).
- Thank you so much. No words can describe our gratitude (Egypt).
- The approach and variety of cases was amazing (Kuwait).
- Good Learning. Thank you Dr. Khan & team DKT for your commitment to teaching (Pakistan).
- Thank you to the presenter and organising team (UK).
- A very good teaching session (Nigeria).
- Impressive (Kuwait).
- Excellent comparison of different pathologies or differentials at the same time (Pakistan).
- Great revision (UK).
- Excellent, very useful. I'm grateful (UK).

## Chest X-Ray For FRCR Exam Part-2

- Very informative. Thank you (Sri Lanka).
- All good (Pakistan).
- It was perfect (UAE).
- It's great (Egypt).
- I liked the FRCR 2B viva style cases (UK).
- Interactive cases (UK).
- Very elaborative (Pakistan).
- Good coverage of cases (Jordan).
- I liked the case selection and the feedback style (UK).
- Great cases (Iraq).
- Excellent detail (Pakistan).
- Good and encouraging environment (Pakistan).
- It was perfect (UAE).
- Beautifully explained X-rays regarding how to elicit signs and give DD (Egypt).
- All of the lecture infections and mediastinal pathologies were useful (Pakistan).
- Extensive course content with tips for DDs (Pakistan).
- Informative discussion (UK).
- Excellent collection of X-Rays. Most topics were covered (India).
- Excellent material (India).
- Reasoning of the radiological findings was great (Pakistan).
- All of it was very useful & highly valuable (Egypt).
- Really good cases (UK).
- The exam and day to day cases and their differentials and diagnosis were great (Pakistan).
- Number of cases was amazing (India).
- All aspects were good (UAE).
- I liked the patient teaching style (Nigeria).
- Explanation of the cases was excellent (Pakistan).
- Every aspect was useful (Sri Lanka).
- Cases selection is excellent (Pakistan).
- I liked the presenter and his cases (Pakistan).
- Excellent teaching style and cases (Pakistan).
- Wonderful session (Pakistan).
- Excellent session (Nigeria).
- Excellent class (Pakistan).
- Very good! (UK).
- Great lecture (Zimbabwe).
- Excellent forum for learning radiology (Pakistan).
- I liked the explanation of differential diagnosis (Singapore).
- Numerous interesting chest radiographs and discussion shared (Malaysia).
- Good case discussion and differentials (Pakistan).
- Great cases (Netherlands).
- Excellent discussion of every case by teacher (Pakistan).
- Many images from cases that often appear in the exam (UK).
- Excellent session (Saudi Arabia).
- Very good revision of basic concepts (Pakistan).





=====XX=====XX=====